

Case Report

Non-purulent pharyngitis: adult still's disease

Nagabhushanarao B. V^{1*}, Narmada Vatti², Naveen Kumar Dannana³, Surendra Konathala⁴

¹Department of Medicine, Queens NRI Hospital, Vishakhapatnam, India

²Department of ENT, Andhra Medical College, Vishakhapatnam, India

³Department of ENT, Queens NRI hospital, Vishakhapatnam, India

⁴Department of Respiratory Medicine, Queens NRI Hospital, Vishakhapatnam, India

Received: 24 June 2020

Accepted: 31 July 2020

*Correspondence:

Dr. Nagabhushanarao B. V.,

E-mail: bhavanavnrao@gmail.com

Copyright: © the author(s), publisher and licensee Medip Academy. This is an open-access article distributed under the terms of the Creative Commons Attribution Non-Commercial License, which permits unrestricted non-commercial use, distribution, and reproduction in any medium, provided the original work is properly cited.

ABSTRACT

Adult Still's disease is rare and may present as pyrexia of unknown origin. Due to lack of expertise, diagnosis may be delayed inadvertently. The patient usually presents with spiked fever, polyarthralgia or arthritis, evanescent skin rash, non-purulent pharyngitis, lymphadenopathy and hepatosplenomegaly. Leukocytosis, predominantly of neutrophils, elevated erythrocyte sedimentation rate and C-reactive protein without obvious infection are the hallmarks of the disease. Delay in diagnosis may expose the patient to the side effects of antibiotics as they are repeatedly prescribed in view of elevated leukocytes. The majority of patients report pain in the throat without evidence of infection. This was an important clue to our diagnosis of this patient. Grossly elevated serum ferritin is diagnostic of adult onset still's disease. As the white cell counts are grossly elevated, a bone marrow examination to rule out hematological malignancy may be mandatory. Serum ferritin value has prognostic value too. Minor illness may respond to non-steroidal anti-inflammatory drugs (NSAIDs), but steroids are the mainstay of the treatment. Methotrexate is of additional value for those presenting predominantly with arthritis. Anakinra, Infliximab and Tocilizumab are other options. Those patients presenting with severe disease and organ involvement require high dose intravenous steroids followed by high dose oral steroids.

Keywords: Adult Still's disease, Non-purulent pharyngitis, Polyarthralgia, Serum ferritin, Spiky fever

INTRODUCTION

Still's disease was first described by George Still in children in 1896, known as juvenile rheumatoid arthritis.¹ In 1971 Adult Still's disease was coined when it occurred in a series of adult patients. Adult Still's disease (ASD) is an-inflammatory disease characterized by daily (quotidian) fever, arthritis and an evanescent rash. The aetiology of it is unknown, though many infections and genetic factors are thought to be triggers. It is a rare disease with an estimated annual incidence of 0.16 cases per 100,000 people with equal distribution amongst the sexes.² The peak incidence is between ages of 15 and 25 and between 36 and 46.

Clinical course of Adult Still's disease can be divided into three patterns: monophasic, intermittent and chronic.

Approximately one third of patients fall in each category, though some studies show chronic arthritic form to be more common.³ Monophasic one is supposed to be of short duration, the chronic one with prolonged illness and intermediary is the intermittent pattern. Fever, rash and arthritis are the cardinal features of ASD each occurring almost in 75 to 95 percent of patients. Fever of ASD is usually single spiked and at times may have double spikes and of short duration. Very high-grade fevers are characteristic of monophasic variety.⁴ The classical skin rash of ASD is macular or maculopapular, evanescent, salmon coloured and non-itchy and tends to occur along with the fever. Arthritis or arthralgia may be mild initially. The most commonly involved joints are the knees, wrists, ankles, elbows, shoulders and proximal interphalangeal joints and in some patient's, arthritis can be very severe and destructive. Myalgia is often worse at the height of

fever, elevated serum creatinine kinase is rarely found and, if at all marginally. A severe nonsuppurative pharyngitis is common in ASD. Hepatosplenomegaly, lymphadenopathy and abnormality in liver function tests are common.⁵ Pulmonary infiltrates, pericarditis and pleural effusions have been observed in 30 to 40 percent of patients. Macrophage activation syndrome (MAS) can occur in 15 to 20 percent of patients of ASD at any stage of illness or can present together.⁶ Renal involvement with proteinuria and cerebral involvement with seizures have been described.

Characteristic laboratory findings include leucocytosis of more than 15,000 with predominant neutrophilia, thrombocytosis and normocytic normochromic anaemia. Marked elevation of acute phase reactants, erythrocyte sedimentation rate (ESR) and c-reactive protein (CRP) is universal. ASD has been associated with markedly elevated serum ferritin levels and has diagnostic as well as prognostic value. The percentage of ferritin that is glycosylated tends to be lesser than in other rheumatic diseases. A classic radiological feature of Adult Still's is a non-erosive narrowing of the carpometacarpal and intercarpal joint spaces of the wrist. Fluorodeoxyglucose-positron emission tomography (FDG-PET) scans may reveal an increased uptake in lymph nodes and salivary glands.⁷

Therapeutic decision should be based upon the intensity of the disease and extent of organ involvement. Subsequent treatment management of the disease depends on the response to treatment. Patients with mild disease may respond to naproxen and ibuprofen in adequate doses, but only 20 percent patients fall in this category. If non-steroidal anti-inflammatory drugs (NSAIDs) treatment alone is ineffective in two weeks, glucocorticoids are to be added to the regimen. Prednisone 0.5 to 1 mg/kg is the usual starting dose, not exceeding 80 mg/day. Patients with severe disease may be started on steroids from the onset. Non responders to glucocorticoids within two months of treatment, or those who have predominantly arthritic symptoms or erosive arthritis may require methotrexate in addition. Those who have severe disease without significant arthritis will benefit from anakinra 100 mg/day, administered as a subcutaneous injection. Tocilizumab is an alternative for those who do not respond to anakinra. For those who respond to anakinra but do not tolerate it, canakinumab is an alternative. In patients who do not respond to methotrexate after three months of maximum tolerated dose, TNF inhibitor infliximab needs to be added. In patients with severe disease with organ involvement high dose intravenous pulse glucocorticoids followed by high dose oral steroids and Anakinra are preferable.⁸

CASE REPORT

A forty-four-year-old male was admitted with a history of fever of one month's duration. Fever was spiky and associated with body pain, throat pain and cough (Figure 1). Fever was of usually one spike or maximum of two

spikes in a day and often relieved with acetaminophen 650 mg taken orally. It was not associated with chills or rigors.

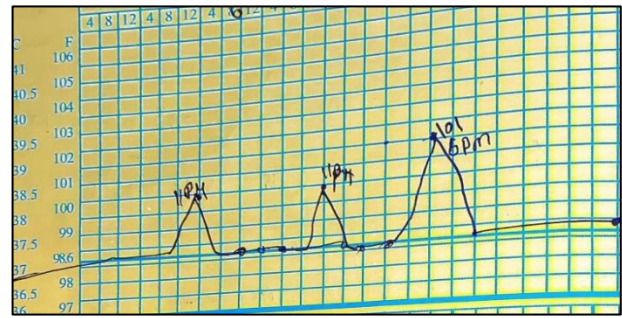


Figure 1: Temperature chart displaying spikes

He had arthralgia during fever but had no active arthritis. He often had pain in his neck and shoulders during fever. The cough was non-productive and often followed the act of swallowing. Even before the onset of fever, he occasionally had cough on exposure to dust or cold weather. Throat pain was severe and persistent all the time and most annoying of all the complaints. There were no swellings in the neck. He had mild burning micturition during fever. Appetite was normal and there were no gastrointestinal symptoms. He had streaky haemoptysis once, during a bout of violent cough.

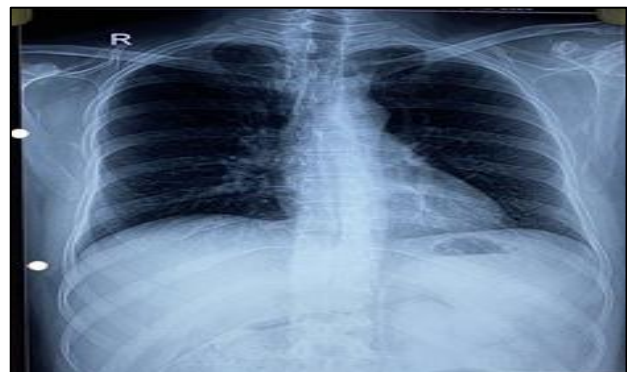

Figure 2: Chest X-ray preview- no abnormality.

Four days after the onset of fever, he consulted a physician at his hometown. In view of fever and body pain he was suspected to have viral fever and was given diclofenac and acetaminophen. He was relieved temporarily, but the illness relapsed. He was admitted to a hospital in view of persistent fever. He was tested for malaria, enteric fever and viral fevers (influenza A and B, parainfluenza, respiratory syncytial and swine influenza viruses) which tested negative. Blood and urine cultures were sterile. Chest X-ray was normal, and Hbs Ag and HIV were seronegative (Figure 2). His blood film showed high leucocytosis with predominant polymorphonucleocytes. His ESR (erythrocyte sedimentation rate) was high and urine showed 10 to 15 pus cells under microscope. Hence, he was suspected to have a urinary tract infection and was advised a course of piperacillin-tazobactam 4.5 gram

intravenously eighth hourly, Amikacin 750 mg once daily for five days and paracetamol 650 mg to be taken if febrile. Despite all these interventions he was febrile with spiky fever. He consulted our hospital outpatient department for evaluation of his fever and high white cell count. His blood counts and peripheral blood smears were re-examined only to find significant polymorpholeukocytosis without any abnormal cells. Contrast tomography (CT) scans of the chest and ultrasound examination of the abdomen did not reveal any abnormality. In an ultrasound scan of the

patient's neck there were a few nonspecific cervical lymph nodal enlargement. Bone marrow aspiration showed hypercellular bone marrow with myeloid hyperplasia but no evidence of leukaemia or infiltrative disease (Figure 3). As there was no evidence of haematological malignancy, he was reluctant to be hospitalized and went home. He was advised to take doxycycline 100 mg, cefditoren 200 mg and etodolac 200 mg twice a day for five days. Fever initially responded to this regimen but relapsed once anti-inflammatory drugs were stopped.

Table 1: Lab investigations.

Lab investigations	22-2-2020	03-03-2020	2-03-2020	26-03-2020	06-06-2020
WBC (cells/cumm)	24,000	25,900	23,420	22,400	13,400
Polymorphs (%)	83	90	90	85	73
ESR (mm/hour)	-	135	-	85	9
CRP (mg/ml)	-	-	-	276	0.48
Serum ferritin (ng/ml)	-	-	-	3,000	95

He was admitted to the hospital with a spiky fever of two days duration. He was kept under observation with an hourly temperature chart. The patient was referred to ENT surgeon in view of persistent throat pain, who couldn't find any evidence of infection in upper airways. Skiagram of paranasal sinuses was normal. Upper gastrointestinal endoscopy revealed sliding hiatus hernia with reflux esophagitis was evident, which might be the reason for the cough after food. The peripheral blood film showed significant neutrophils but no abnormal cells. Blood and urine cultures did not reveal any growth. There was no evidence of endocarditis on echocardiography (ECHO). ESR was 85 mm/ 1st hour, CRP was 276 mg/L and Mantoux test was negative. In view of fever, polyarthralgia and elevated inflammatory markers rheumatoid factor assay and Antinuclear antibody profile by the immunoblot method were done. Both were negative.

At this stage of evaluation of the disease we were unable to come to any specific conclusion regarding the nature of his illness. We analysed all his clinical and laboratory data once again from the beginning of his illness. We also looked into the Oxford textbook of medicine to reorient ourselves with the list of various diseases presenting as pyrexia of unknown origin (PUO).

The patient initially presented with spiky fever, polyarthralgia and persisting throat pain. His leukocyte count was elevated with predominant polymorphs. Inflammatory markers were elevated and there was no evidence of rheumatological illness or any specific infection. A severe nonsuppurative pharyngitis had been troubling him throughout his illness. At this stage, taking clues from throat pain, fever, polyarthralgia, elevated polymorphs and elevated inflammatory markers we

suspected adult's onset Still's disease and asked for serum ferritin, which was reported as 3,000 ng/ml (12-300) ng/ml. Authors started him on prednisone 60 mg per day orally. He responded dramatically, fever, myalgia and throat pain subsiding, within forty-eight hours. He was discharged home on the same dose of Prednisone. He was reviewed six weeks later. He was asymptomatic, his blood ESR, CRP, leucocyte count and serum ferritin levels were normalised (Table 1).

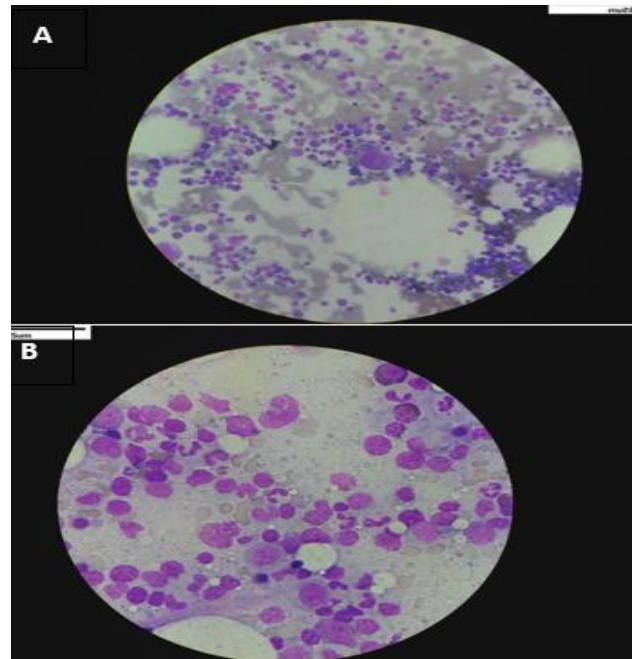


Figure 3. Bone marrow examination- hypercellular with myeloid.

DISCUSSION

Adult Still's disease is rarely encountered in physician's practice and may not be so in rheumatology practice. Hence it culminates in a diagnostic problem when presenting as (PUO). In one study, fifteen percent of all the cases that were admitted over a period of 18 years in an institute, fulfilled the criteria for ASD. It was suggested to consider ASD if a patient presented with fever, rash, throat pain and arthralgia during the diagnostic work up of PUO.⁹ Temperature swings are typically dramatic in this condition as was found in our patient. This further emphasizes the importance of maintaining temperature records diligently. The classical skin rash that was seen along with fever in ASD was absent in our patient. Our patient had arthralgia but no active arthritis. Arthralgia was mild and was associated with febrile illness. In some patients it may progress to destructive arthropathy.¹⁰ Myalgias are common in ASD and our patient had pain in the neck and shoulder during fever.

A severe nonsuppurative pharyngitis is more common and it is reported in up to 95 % of patients in one series.^{11,12} Persistent throat pain actually gave a clue to the diagnosis of our patient. Hepatosplenomegaly was reported in 12 to 45 percent of patients and abnormal liver function up to 75% of patients. This case patient showed an elevation of alkaline phosphatase but no change in aminotransferases. Though the patient had cough there was no evidence of pleuropulmonary or pericardial disease. One half of the patients may have cervical lymphadenopathy and may show distinct para cortical immunoblastic hyperplasia on histopathological examination.¹³ Though our patient had cervical lymphadenopathy biopsy was not attempted as they were not clinically significant.

The leucocytosis is an acute phase response in ASD. Our patient had a white cell count of more than 15,000, predominantly of polymorphs. Often persistent neutrophilia in a febrile patient leads to repeated antibiotic administration. Hyper cellular marrow with myeloid hyperplasia is usually seen on bone marrow examination of ASD, as evident in our patient.¹⁴ Our patient had grossly elevated ESR and C- reactive protein, this phenomenon is seen in most patients of ASD.¹⁵ In more than 75 percent of ASD patients serum ferritin is grossly elevated, detection of ferritin values above 3000 mg/L should lead to consideration of Adult still's disease.¹⁶ Antinuclear antibodies and rheumatoid factors were negative in this patient, a requisite confirming the diagnosis of ASD.

The differential diagnosis includes acute viral syndromes, bacterial infections, endocarditis, rheumatological disorders, vasculitis, malignancy and drug reactions. Leukopenia, neutropenia, lymphopenia and thrombocytopenia differentiate hemophagocytic lymph histiocytosis from Macrophage Activation Syndrome (MAS) that arises in ASD. In both the conditions serum ferritin is grossly elevated.

Yamaguchi criteria are often used to make a diagnosis of ASD.¹⁷ This case patient had fever and arthralgia of more than four weeks duration, leucocytosis with 80% granulocytes, (three major) sore throat, lymphadenopathy and negative tests for antinuclear antibody and rheumatoid factor (three minor).

The patient responded well to prednisone 60 mg per day. He was reviewed after 6 weeks, and he was asymptomatic and attending regular duties. If he had not responded to steroids, anakinra or tocilizumab were alternatives.¹⁸

The goals of therapy include control of physical signs and symptoms, control of laboratory indices of inflammation, prevention of end organ damage and minimizing the risk of adverse effects of the drugs.

CONCLUSION

One should keep in mind the possibility of Adult Still's disease when managing a fever of unknown origin. Persistently elevated neutrophils, typical fever pattern, skin rash and elevated ferritin levels point towards Still's disease. A non-purulent pharyngitis is of additional diagnostic value. A careful look at the temperature chart is always rewarding to the clinician.

ACKNOWLEDGEMENT

Authors thank chairperson Queens NRI Hospital, Visakhapatnam Dr. C. Vijayalakshmi FRCOG (Glasgow) for permitting to publish the case.

Funding: No funding sources

Conflict of interest: None declared

Ethical approval: Not Required

REFERENCES

1. Still GF. On a form of chronic joint disease in children. Med Chir Trans. 1897;80:47-60.
2. Magadur-Joly G, Billaud E, Barrier JH, Pennec YL, Masson C, Renou P, et al. Epidemiology of adult Still's disease: estimate of the incidence by a retrospective study in west France. Ann Rheum Dis. 1995;54(7):587.
3. Gerfaud-Valentin M, Maucort-Boulch D, Hot A, Iwaz J, Ninet J, Durieu I, et al. Adult-onset still disease: manifestations, treatment, outcome, and prognostic factors in 57 patients. Med. 2014;93(2):91.
4. Calabro JJ, Marchesano JM. Fever associated with juvenile rheumatoid arthritis. N Engl J Med. 1967;276(1):11.
5. Gerfaud-Valentin M, Jamilloux Y, Iwaz J, Sève P. Adult-onset still's disease. Autoimmun Rev. 2014;13(7):708-22.
6. Bae CB, Jung JY, Kim HA, Suh CH. Reactive hemophagocytic syndrome in adult-onset still

- disease: clinical features, predictive factors, and prognosis in 21 patients. *Med.* 2015;94(4):e451.
7. Gerfaud-Valentin M, Maucort-Boulch D, Hot A, Iwaz J, Ninet J, Durieu I, et al. Adult-onset still disease: manifestations, treatment, outcome, and prognostic factors in 57 patients. *Med.* 2014;93(2):91.
 8. Mert A, Ozaras R, Tabak F, Bilir M, Ozturk R, Ozdogan H, et al. Fever of unknown origin: a review of 20 patients with adult-onset Still's disease. *Clin Rheumatol.* 2003;22(2):89.
 9. Elkon KB, Hughes GR, Bywaters EG, Ryan PF, Inman RD, Bowley NB et al. Adult-onset Still's disease. Twenty-year followup and further studies of patients with active disease. *Arthritis Rheum.* 1982;25(6):647.
 10. Pouchot J, Sampalis JS, Beaudet F, Carette S, Décarry F, Salusinsky-Sternbach M, et al. Adult Still's disease: manifestations, disease course, and outcome in 62 patients. *Med.* 1991;70(2):118.
 11. Nguyen KH, Weisman MH. Severe sore throat as a presenting symptom of adult onset Still's disease: a case series and review of the literature. *J Rheumatol.* 1997;24(3):592.
 12. Valente RM, Banks PM, Conn DL. Characterization of lymph node histology in adult onset still's disease. *J Rheumatol.* 1989;16:349.
 13. Min JK, Cho CS, Kim HY, Oh EJ. Bone marrow findings in patients with adult Still's disease. *Scand J Rheumatol.* 2003; 32:119.
 14. Ohta A, Yamaguchi M, Tsunematsu T. Adult Still's disease: a multicenter survey of Japanese patients. *J Rheumatol.* 1990;17:1058.
 15. Schwarz-Eywill M, Heilig B, Bauer H, Breitbart A, Pezzutto A. Evaluation of serum ferritin as a marker for adult still's disease activity. *Ann Rheum Dis.* 1992;51(5):683.
 16. Yamaguchi M, Ohta A, Tsunematsu T, Kasukawa R, Mizushima Y, Kashiwagi H, et al. Preliminary criteria for classification of adult Still's disease. *J Rheumatol.* 1992;19(3):424.
 17. Fautrel B. Adult-onset still disease. *Best Pract Res Clin Rheumatol.* 2008; 22:773.

Cite this article as: Nagabhushanarao BV, Vatti N, Dannana NK, Konathala S. Non-purulent pharyngitis: adult still's disease. *Int J Res Med Sci* 2020;8:3362-6.